

UNKNOWN RETINA STUDIES IN 19TH CENTURY POLAND

Short title: *Unknown retina studies*

Andrzej Grzybowski,^{1,2} MD, PhD

Abstract

Introduction: *Despite political restriction of higher education and scholarly activity in 19th C. Poland, contributions by Polish ophthalmologists were made.*

Methods: This historical study is based on analysis of original 19th century ophthalmologic texts and other literature of the subject.

Results: This report describes little known advances in retinal physiology and pathology in Poland, as well as the development of two innovative instruments. In clinical ophthalmology Kramsztyk described circumpapillary cilioretinal anastomoses in central retinal artery occlusion; Bałaban indicated that there is no spontaneous pulsation in central retinal vein occlusion; Ziemiński described independently the interesting patients with Eales' disease; Rumszewicz discussed diagnostic difficulties leading to erroneous enucleation in retinoblastoma suspected patients. The studies of Nikolski and Dogiel represented the third earliest good quality fundus photography. Szokalski designed a device for measuring retinal light sensitivity and Noiszewski an "electrophthalm", which was supposed to convert the visual stimuli provided by bright and illuminated objects into tactile ones.

Conclusions: Polish ophthalmologists made interesting observations and innovations in retinology, however, much of their work was not known to international ophthalmology because it was not translated into a foreign language.

Introduction

Events that took place during the 19th century were vital for the development of modern ophthalmology and for studying the most important structure responsible for vision, the retina. The invention of the ophthalmoscope by Hermann von Helmholtz in 1850 made it possible to study the anatomy and pathology of the fundus of the eye. This boosted the development of ophthalmology in many countries, including Poland. However, Poland was not independent at that time as it was partitioned and occupied by its three neighbours: Russia, Prussia and Austria. The two partitions (the First in 1772 and the Se-

cond in 1793) significantly limited the area of Poland, however it was the Third Partition of 1795, which extinguished an independent Poland.

Medical studies in Poland have a long tradition and they date back to the establishment of the Academy of Cracow in 1364. The Jagiellonian University that was a continuation of the Academy of Cracow was the only university that was not closed in Poland in the 19th century. Many foreign researchers studied and worked at this university. One such researcher was Johann Nepomuk Rust (1775-1840), a respected teacher of ophthalmic and general surgery, who worked as a professor of surgery in Cracow in the years 1803-1809. Finally he was given a professorship of surgery at the Berlin University. He was a tutor of many prominent surgeons dealing with ophthalmology, including Diefenbach and Bierkowski⁽¹⁾.

Another prominent researcher who was connected with Cracow was Carl Ferdinand von Graefe, the father of Albrecht. He was born in Warsaw and studied in Cracow. In 1822 he was planning to become the head of the division of surgery in Warsaw⁽²⁾.

However, the situation of all the remaining Polish universities was much more

Andrzej Grzybowski, MD, PhD, MBA
Consultant Ophthalmologist
Head of the Dept. of Ophthalmology
Dept. of Ophthalmology,
Poznan City Hospital,
ul.Szwajcarska 3,
61-285 Poznań, Poland
e-mail: ae.grzybowski@gmail.com

¹Department of Ophthalmology,
Poznań City Hospital, Poland

²Chair of Ophthalmology, University of Warmia and Mazury,
Olsztyn, Poland

Author has conflict of interest with the submission.

No financial support was received for this submission.

complicated. For instance, the Faculty of Medicine of the Vilnius University (that was established with a support of Johan Peter Frank (1745-1821), an outstanding Austrian physician known for his pioneering works on hygiene, epidemiology and forensic medicine) was shut down many times and it was finally closed by Alexander II, the Tzar of Russia. Lviv University did not have a medical faculty at that time at all.

In Warsaw, medical studies were initiated in 1809 in the Academy of Medicine. However, the Academy was closed after the November Uprising in 1831 for 26 years. Next, in 1857 the Academy of Medicine and Surgery was established, yet it was closed four years later, after the January Uprising in 1863. In 1869 the Russians started the Tzar's Warsaw University. The official language of the university was Russian and its lecturers were Russian. The Tzar's Warsaw University was composed mainly of Russian teachers of lesser scientific status, with the exception of Piotr Nikolsky (known for his Nikolsky sign distinguishing pemphigus vulgaris from bullous pemphigoid). This soon gave the University a reputation of a lower quality of education, leading most Poles to study medicine in Dorpat or St Petersburg. Obviously, this extremely difficult situation of higher education in Poland had an enormously negative impact on Polish science. In addition to the fact that the occupying powers made it impossible to study medicine in Poland, Polish ophthalmology centers were only allowed to perform clinical work without research or experimental activities.

In spite of such hard conditions, Polish ophthalmologists still managed to work in the field and carry out some research. Among the most prominent ophthalmologists with most valuable contributions to the field in the 19th century were: Wiktor Szokalski, MD (1801- 1891) in Warsaw, Antoni Sławikowski, MD (1796-1870) (J. Beer's student from Vienna) and Lucjan Rydel, MD (1838-1895) (F. Arlt's student from Vienna) in Cracow, Bolesław Wicherkiewicz, MD (1847-1915) in Poznan and later in Cracow, and Emanuel Machek, MD (1852-1930) (F. Arlt's student from Vienna) in Lviv. Thanks to their considerable achievements in ophthalmology, these researchers gained high professional prestige not only in Poland, but also abroad.

They and their students had a decisive influence on Polish ophthalmology of the period. Some of their forgotten achievements were described recently⁽³⁾. Others, little known because published only in Polish language, are brought into international recognition in this study.

Little known Polish publications in study of the retina

The political situation of Poland in the 19th century led to a situation in which many outstanding works by Polish ophthalmologists were published only in Polish and never translated into any other language. As a consequence, their accessibility was restricted and they were hardly known in international ophthalmology.

Józef Majer (1808 – 1899) was a physician and a physiologist. He was a professor and a provost of the Jagiellonian University in Cracow. Majer wrote two exceptionally important textbooks on the physiology of the nervous system: *The Physiology of the Nervous System* (Warsaw, 1854) and *The Physiology of Senses* (Cracow – Warsaw, 1857)⁽⁴⁾. In the second textbook he presented an in-depth and innovative discussion of different aspects of retinal activity⁽⁴⁾. The textbook was highly valued by most prominent researchers, such as Jan Ewangelista Purkyně and Napoleon Cybulski (a famous Polish physiologist and discoverer of epinephrine).

In 1895 Zygmunt Kramsztyk described circumpapillary cilioretinal anastomoses (the so called Nettleship collaterals) in central retinal artery occlusion⁽⁵⁾. Nettleship was the first to describe this type of collateral in 1891⁽⁶⁾, and Kramsztyk's publication was probably the second one in the world literature. Yet, since it was published in Polish only, it was not available for international ophthalmology.

In 1900, Teodor Bałaban published a comprehensive paper on central retinal artery occlusion⁽⁷⁾. Bałaban ascribed considerable importance to the pulsation of the venous and arterial vessels: "Vascular performance is an incredibly typical symptom when pressure is applied to the eyeball. Therefore, as small pressure is applied with a finger to the eyeball proper, first the veins located on the

optic disc begin to pulsate and then the arteries, and again, when pressure increases, the vessels empty respectively. Pressure on the eyeball in retinal vein occlusion does not cause any pulsation in veins and these empty very unusually. In arteries it is only by applying very strong pressure that it is possible to cause pulsation. This important symptom is a necessary and direct follow-up of the central vein occlusion and increased arterial blood pressure." Bałaban's observation indicating that there is no spontaneous pulsation in central retinal vein occlusion and concerning the influence of the eyeball pressure on veins and arteries pulsation in the eye fundus were very accurate.

Another Polish researcher and author of ophthalmic textbook "Outline of ophthalmology" (Warsaw, 1909), Bronisław Ziemiński, MD (1860-1915), contemporaneous with Eales, described the patients with Eales' disease⁽⁸⁾ independently only a few years after Eales did^(9,10). Ziemiński discussed in depth vitreous haemorrhages of unknown origin in young patients in his paper published in 1888⁽⁸⁾. He presented five cases characterized by a sudden and usually painless vitreous haemorrhage (with tendencies for recurring and for bilaterality) in young males with no history of sexually transmitted diseases nor tuberculosis⁽⁸⁾. The laboratory tests of these males were unremarkable, so that diabetes and nephritis could be ruled out. Yet, some vascular dysfunctions were observed: "a flush in the head (occurring especially after meals), accompanied by a splitting headache, and sometimes by a vertigo, and a concurrent feeling of cold in the upper and lower limbs"⁽⁸⁾. The patients also suffered from constipation and epistaxis.⁽⁸⁾ The outer appearance of the eye was unremarkable. The ophthalmoscopic picture was not clear enough, yet the author suggested that the haemorrhage originated from the peripheral parts of the eye fundus (8). Besides, the retinal vessels (mainly the venules) showed considerable tortuosity and thickness in both eyes, especially in the one affected by the haemorrhage. The retinal venules were of a dark-red colour. The nearer the site of the ruptured vessel, the bigger the tortuosity of the venules could be seen⁽⁸⁾.

In 1891, Rumszewicz published a comprehensive and interesting work on the diagnosis of retinoblastoma⁽¹¹⁾. In the 19th

century the suspicion of retinoblastoma led to the removal of the eyeball. On the basis of some foreign studies as well as his own cases, Rumszewicz described diagnostic difficulties leading to erroneous enucleation. He advocated that it was only after the histopathological investigations that the final diagnosis of the cases was possible.

The *in vivo* anatomical studies were closely related to the advancement of ocular fundus photography. Retinal photography can be dated to the first attempts by Henry Noyes in 1862⁽¹²⁾. The first publication in Polish on the subject was a paper by Nikolajew and Dogiel⁽¹³⁾. The paper was written in Professor Jan Dogiel's (1830 – 1905) laboratory in Kazań. Professor Dogiel was Hermann von Helmholtz's student and co-worker, and then became a famous Polish physiologist and pharmacologist. In their paper the authors discussed their first attempts to photograph the retina in 1897 and provided fundus pictures of cat's eye⁽¹³⁾.

The first published report of human fundus photography was by Jackman and Webster in 1886⁽¹⁴⁾. The image was, however, quite blurry and it was not possible to discern any details. The early progress toward better quality of images was due to works of Howe⁽¹⁵⁾, Barr⁽¹⁶⁾ and Gerhoff⁽¹⁷⁾, however the first two did not publish their original fundus photographs. The Gerhoff paper was the first to present photos allowing analysis of some fundus details, including optic disc and blood vessels⁽¹⁷⁾. Although some further development was reported in the late 19th century studies by Dimmer and Thorne, the major studies were published at the beginning of the 20th century^(18,19).

The studies of Nikolski and Dogiel⁽¹³⁾, previously not recognized in historical analysis of this issue^(20,21), presented a relatively good quality image of the fundus. Thus, after Gerhoff and Dimer, it was the third report documenting good quality fundus photograph.

Scholarly and scientific limitations in politically non-existent Poland

Only three ophthalmology textbooks were published in Poland during the 19th century. Among these three, only one was originally written in Polish, by Szokalski⁽²²⁾. Wiktor Szo-

kalski, MD (1811-1891) (Fig.1.), one of the most outstanding Polish ophthalmologists, presented his doctoral dissertation at the University of Giessen in Germany (Fig.2). Then, he worked for many years in France




Fig. 1.
Wiktor Szokalski (1811-1891).

(Library of Dept. of History of Medicine,
Poznań University of Medical Science, Poland).

where he had to retake his final medical exam in order to practice. Finally, he came back to Poland and settled in Warsaw, which was under the Russian rule at that time. There, he had to sit for his medical examinations for the third time, because Russians did not accept his former medical certificates issued in Germany and in France.

The remaining two textbooks were not written by Polish authors but they were translated into Polish. These were the textbooks by Louis de Wecker, MD (Fig.3) (23) and Eduard Meyer, MD (Fig.4) (24). The books contained a wide spectrum of knowledge on the retinal structure and function, yet they were academic books, rather than scientific monographs.

Polish ophthalmologists were deprived of research tools in basic sciences and carrying out any research was hardly possible. They had to limit their scientific endeavours to discussing clinical aspects of physiology and physiopathology of vision. Here, we can

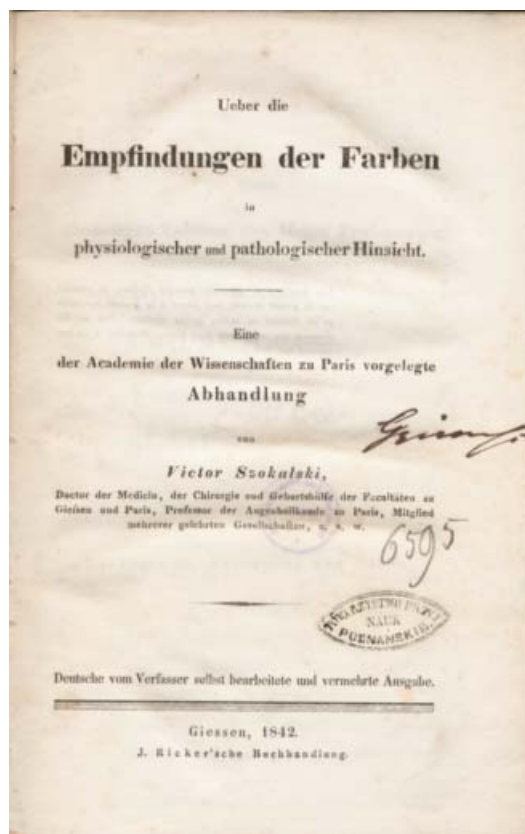

Fig.2.
Frontpage of *Ueber die Empfindungen der Farben* by Szokalski, Giessen 1842

(Library of the Poznań Society of Friends of Humanities).

mention Szokalski's dissertation on the physiology and pathology of colour vision (25) and Gałęzowski's paper on color vision studies and their relevance to the diagnosis of eye diseases (26). In the 19th and the 20th centuries both works were regarded as fundamental in Poland. Although some theories in vision physiology and physiopathology were formulated in Poland at that time, due to the lack of a strong research background, they were based on theoretical assumptions and observations.

Little known inventions of Polish ophthalmologists

Polish ophthalmologists had some remarkable inventions that, regrettably, have never been presented abroad, such as a device for measuring retinal light sensitivity designed by Szokalski (27) and an "electrophthalm" (28) invented by Noiszewski.

In 1864, Szokalski introduced "a device of my own idea for measuring retinal light sensi-




Fig.3.
Frontpage of *Ophthalmology according to Wecker*
transl. by W. Narkiewicz-Jodko & B. Gepner,
1869-1870, Warsaw.

(Library of Dept. of History of Medicine,
Poznań University of Medical Science, Poland).

vity”⁽²⁷⁾. The device was composed of “a cylindrical tube and inserted into it, one on top of the other, two dark convexo-concave lenses of uniform thickness. The number of glasses necessary to completely block ordinary stearic candle light is a measure of the so-called sensitivity.”⁽²⁷⁾ Szokalski emphasized the possibility of applying the device in ophthalmology, “since in many eye diseases, e.g. night blindness, iritis [it must be a mistake – what is meant here is retinitis] caused by pigmentosa (retinitis pigmentosa), etc., the already mentioned retinal light sensitivity is reduced, hence, the doctor may want to learn about the level of the reduction at different stages of the disease and its treatment”⁽²⁷⁾. It should be mentioned that the device was a prototype of the retinal light sensitivity examination performed during the modern static perimetry in which, apart from the data on the visual area and its defects, it is possible to obtain some information on the depth of the scotoma, i.e. the degree of retinal sensitivity to light stimuli.

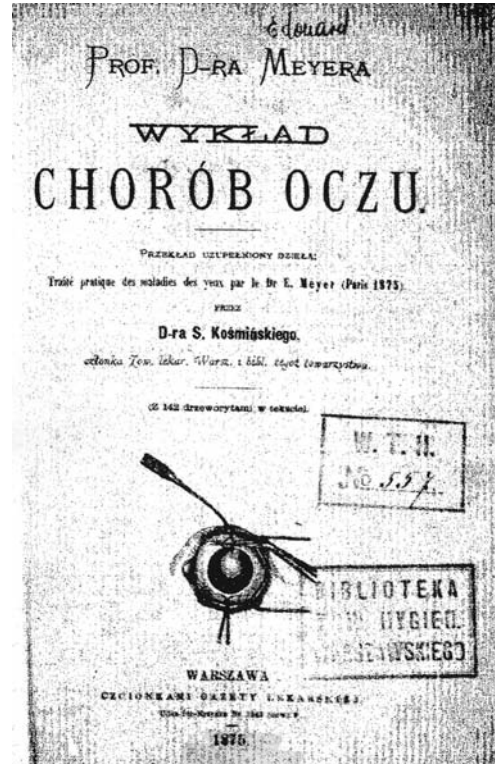


Fig.4.
Frontpage of *Professor Meyer's lecture on eyes*
diseases transl. by S. Koźmiński, 1875,
Warsaw.

(Library of Dept. of History of Medicine,
Poznań University of Medical Science, Poland).

The second device mentioned above, the electrophthalm developed by Kazimierz Noiszewski, MD (1859-1930) (Fig.5), was supposed to convert the visual stimuli provided by bright and illuminated objects into tactile ones⁽²⁸⁾. The method was based on the property of selenium to alter the electric current



Fig.5.
Kazimierz
Noiszewski
(1859-1930).

(Library of Dept. of
History of Medicine,
Poznań University
of Medical Science,
Poland).

conductivity under the influence of light. As a consequence, the electric current was changed into heat which, in turn, was perceived on the forehead glabella. It was then believed that the area was incredibly sensitive to heat and thus capable of sensing changes in temperature within the range of 0.2°C (29). Concluding his description, Noiszewski presented some assumptions that allowed a better understanding of the potential of the device. First of all, he explained the basic rule of work of the device: “the presence of a bright or illuminated object will be sensed as a sensation of heat or as pressure on the skin”⁽²⁸⁾. Second, if it is possible to sense brightness it must also be possible to sense darkness; “a dark object placed against a bright background will be felt as heat and pressure in the periphery of the perceiving surface and as their absence in its centre; the image of the dark object will be negative”⁽²⁸⁾. Third, it will be possible to determine the distance of the bright object, e.g. “an expanding surface of heat sensation, as the bright object approaches” and the other way round: “an increasing surface of hot sensation, as the bright object recedes”⁽²⁸⁾. Fourth, it will be possible to determine changes in the location of the object; “a change in the location of heat sensation towards the right will mean that the object itself has been moved towards the left and the other way round”⁽²⁸⁾. Noiszewski’s idea was very original and although it found only some continuation in practice⁽³⁰⁾, it surely was pioneering.

Conclusions

Polish ophthalmologists made interesting observations and innovations in retinology. However, much of their work was not known to international ophthalmology because it was published only in Polish and not translated into a foreign language.

References

- Galst JM. Johann Nepomuk Rust. *Arch Ophthalmol* 2008; 126:1099.
- Wrzosek A. *Ludwik Bierkowski*. Cracow, 1911, 147.
- Grzybowski A. Forgotten achievements of Polish retinal research in international ophthalmology. *Acta Ophthalmologica* 2012; 90: 193–198.
- Majer J. *Fizjologia zmysłów* [The physiology of senses]. Cracow - Warsaw, 1857, 217-227
- Kramszyk Z. Odcinek siatkówki zachowujący swą czynność przy zupełnym zatorze głównego pnia tętnicy środkowej [A retinal part retaining its function at a complete occlusion of the retinal central artery main trunk]. *Gazeta Lekarska* [Medical Newspaper] 1895; 28: 795-797.
- Nettleship E. Unusual appearance In a case of retinal embolism abort 30 hours after its occurrence. In: *Festschrift zur Feier Siebzigsten Geburtstage Hermann von Helmholtz*, Stuttgart, 1891, 7-8.
- Bałaban T. Zakrzep środkowej żyły siatkówkowej wśród blednicy [Central retinal vein thrombosis in chlorosis. In: *Pamiętnik jubileuszowy wydany ku uczczeniu dwudziestopięcioletniej działalności prof. Edwarda Sas Korczyńskiego* [Jubilee Memoirs to celebrate twenty five years of profesor Edward Sas Korczyński’s work]. Cracow, 1900, 211-224.
- Ziemiński B. O rażeniu krwawem ciała szklistego u osób dorastających [On haemorrhage into the vitreous body in the adolescent]. *Gazeta Lekarska* [Medical Newspaper] 1888; 4: 69-78; 98-106.
- Eales H. Retinal haemorrhages associated with epistaxis and constipation. *Brit Med Rev* 1880; 9: 262.
- Eales H. Primary retinal haemorrhage in young men. *Ophthalmic Rev* 1882; 1: 41.
- Rumszewicz K. O rzekomych glejakach siatkówki [On presumed retinal gliomas]. *Przegląd Lekarski* [Medical Review] 1891; 43: 541-543; 44: 553-555.
- Jeffries BJ. Report on the progress of ophthalmology during the past year. *Trans Am Ophthalmol Soc* 1865; 1: 2-12.
- Nikołajew W, Dogiel N. Fotografowanie siatkówki. Doniesienia tymczasowe. [Retinal photography. Temporal reports]. *Medycyna* [Medicine] 1900; 28: 238-239.
- Jackman WT, Webster JD. On photographing the retina of the living human eye. *Phi-*

- Philadelphia Photographer* 1886; 23: 340-341.
15. Howe L. Photography of the interior of the eye. *Trans Amer Ophth Soc* 1887; 23: 568-571.
 16. Barr E. On photographing of the interior of the human eyeball. *Amer J Ophthalmol* 1887; 4: 181-183.
 17. Gerhoff O. Ueber die photographische des augenuntergrundes. *Klin Monat f. Augenheil.* 1891; 29: 397-403.
 18. Thorner W. *Die Theorie des Augenspiegels und die Photographie des Augenhintergrundes.* Berlin, A. Hirschwald, 1903.
 19. Dimmer F. *Die Photographie des Augenhintergrundes.* Bergmann, Wiesbaden, 1907.
 20. Saine PJ. Landmarks in the historical development of fluorescein angiography. *Journal of Ophthalmic Photography* 1993; 15: 17-23.
 21. Mann W. History of Photography of the Eye. *Surv Ophthalmol* 1970; 15: 179-189.
 22. Szokalski W. *Wykład chorób przyrządu wzrokowego u człowieka* [A lecture on diseases of the sight organ in the human]. vol. 1-2, Warsaw, 1869.
 23. Narkiewicz-Jodko W, Gepner B. *Oftalmologia podług Weckera* [Ophthalmology according to Wecker]. vol. I-II, Warsaw, 1869-1870.
 24. Koźmiński S. *Prof. Dr Meyera wykład chorób oczu* [Professor Meyer's lecture on eyes diseases]. Warsaw, 1875.
 25. Szokalski W. *Ueber die Empfindungen der Farben in physiologischer und pathologischer Hinsicht.* Giessen, 1842.
 26. Gałęzowski K. *Du diagnostic des maladies des yeux par la chromatoscopie rétinienne. Précédé d'une étude sur les lois physiques et physiologiques des couleurs.* Paris, 1868.
 27. Szokalski W. Fotometr własnego pomysłu [A photometer of my own idea]. *Pamiętnik Towarzystwa Lekarskiego Warszawskiego* [Memoirs of the Warsaw Medical Society] 1865; 7: 267-268.
 28. Noiszewski K. Elektroftalm [Electrophtalm]. *Gazeta Lekarska* [The Medical Newspaper] 1889; 9: 1018-1022.
 29. Noiszewski K. Topotermaesthesiometr. *Gazeta Lekarska* [The Medical Newspaper] 1889; 10: 204-205.
 30. W. Starkiewicz, W. Kuprianowicz, F. Petruczenko. 60-channel elektroftalm with CdSO₄ photoresistors and forehead tactile elements. In: Sterling et al. (eds.), *Visual prosthesis: the interdisciplinary dialogue.* New York: Academic Press, 1971, 295-299.

ACKNOWLEDGEMENTS:

The author wish to thank Professor Jean Jacques De Laey and Dr. James Ravin for a discussion of the paper and their supportive comments; Patrick Saine, M.Ed., C.R.A., FOPS for his help in supply of information about history of ophthalmic photography; Professor Waldemar Marton from Poznań College of Modern Languages and Dr Monika Potczyńska from School of English, Adam Mickiewicz University, Poznań for their help with proofreading the English text, and Dr. Albert Franceschetti for his support in supply of Gałęzowski's papers.

